

Breast Mass Classification Based on Opto-acoustic Features Using Data Mining

Philip Lavin; Michael J. Ulissey; David Schoenfeld;
A. Thomas Stavros

Seno Medical Instruments, Inc., San Antonio, TX

Biostatistics, Harvard School of Public Health, Boston, MA

phil_lavin@hotmail.com

atstavros@gmail.com

Background

- Imagio® (Seno Medical Instruments, Inc.) is currently an investigational medical device being tested for FDA review.
- It utilizes dual wavelength laser opto-acoustic imaging technology co-registered with conventional diagnostic ultrasound to gain both structural and functional imaging information of potentially suspicious breast masses without having to administer radioactive contrast agents or expose patients to radiation.
- The purpose of this study is to evaluate clinical applications of opto-acoustic features to classify patients as either having a malignant or benign breast mass by examining morphological and functional features found within and outside the tumor mass, to ultimately spare biopsies.

Material and Method

- A prospective series of 66 cases included 37 histologically proven cancers and 29 histologically proven benign masses.
- Each patient was evaluated on five features by Imagio using a 0-5 ordinal scale.
 - Internal tumor features included density of vascularity (DV), blood oxygen saturation (BO), and the total blood accumulation (BA)
 - External tumor features included boundary zone total blood (TB) and peripheral peri-tumoral radiating vessels (RV);
- Each were scored on a 0-5 ordinal scale and were summed to get a total internal score, total external score, and a total score.
- Five classification methods were used to classify between benign and malignant outcomes:
 - Logistic Regression (LR)
 - Support Vector Machines (SVM)
 - Classification Trees (CT)
 - Random Forests (RF), and
 - K-Nearest Neighbors (KNN).
- Ten-fold cross validation was used where the 66 cases were randomly divided into 10 groups.

Material and Method (2)

- Each of the ten possible groups was removed in turn from the 66 observations and the classifier was trained on the remaining groups to develop a classification rule.
- This rule was then applied to the removed group.
- This process was repeated ten times until every observation was assigned by a classifier that had not previously been developed using that observation.
- A two-sided exact Jonckheere-Terpstra test was used to test the relationship between increasing scores (internal, external, total) and higher cancer grade.

Results

1. The study population consisted of 29 fibroadenomas (FAs) as well as 10 IDC 1, 11 IDC 2, and 18 IDC 3 cases; 66 cases were evaluated for the classification analyses.
2. Results were consistent and favorable for Imagio; there was 100% sensitivity with 72% to 79% specificity (Table 1).
3. KNN and SVM performed the best while LR performed the worst.
4. The probability of malignancy for these methods decreased depending on the variables with negative coefficients and increased with those with positive ones. The coefficients for BA and DV were statistically significant. The importance of these coefficients for the other methods was consistent.

Results (2)

5. The probability of malignancy further depended on the internal tumor features but not on the external features (Figures 1-3).

- OA Total (two-sided $p=3 \times 10^{-8}$) and OA Total Internal (two-sided $p=6 \times 10^{-9}$) were highly significant, but not OA Total External
- OA Total and OA Total Internal Features were highly related to histology with lower scores for FAs increasing progressively to highest scores for IDC 3.
- All three internal OA features were highly significant: (1) DV (two-sided $p=10^{-7}$), BO (two-sided $p=3 \times 10^{-8}$), and BA (two-sided $p=5 \times 10^{-6}$).
- The cumulative contribution of each internal feature to the total internal score was also assessed for each histopathology subgroup to confirm independent contribution to the OA Total Internal Score; pairwise correlations explained no more than 56% of the total variance.

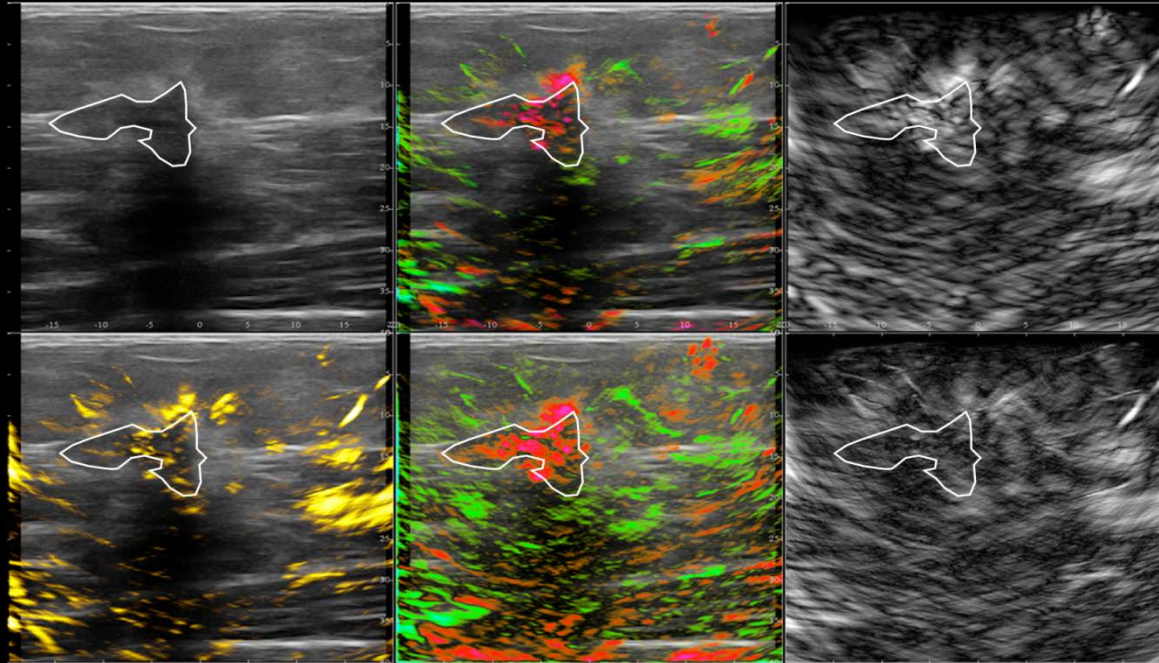
Findings support the stand-alone biopsy-sparing potential for Imagio.

Table 1

Method	Malignant Classified as Benign	Benign Classified as Malignant	Sensitivity	Specificity
Logistic Regression	2	14	95%	52%
Support Vector Machine	0	6	100%	79%
Classification Trees	1	10	97%	66%
Random Forest	0	8	100%	72%
K Nearest Neighbor	0	6	100%	79%

Table 1 illustrates a summary of the five classifications methods used to categorize between malignant and benign findings

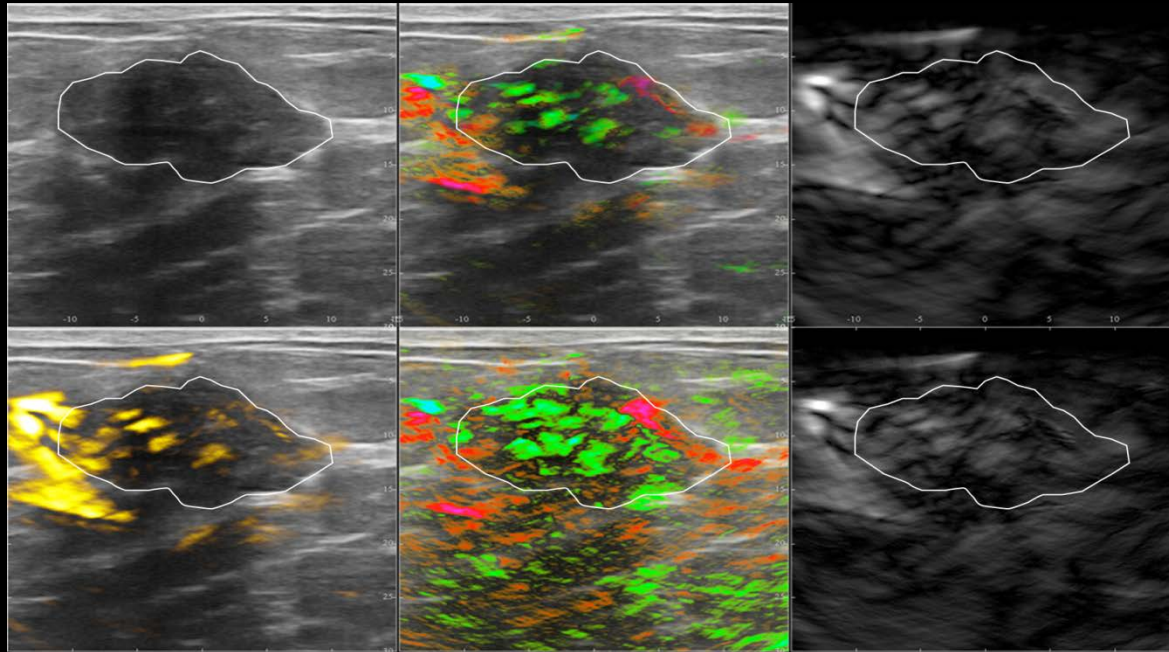
IDC Grade 2 – Imagio – BI-RADS 5



seno
MEDICAL INSTRUMENTS INC.™

Figure 1 displays an IDC grade 2 with numerous internal red vessels, internal red blush, increased internal blood and peri-tumoral radiating vessels.

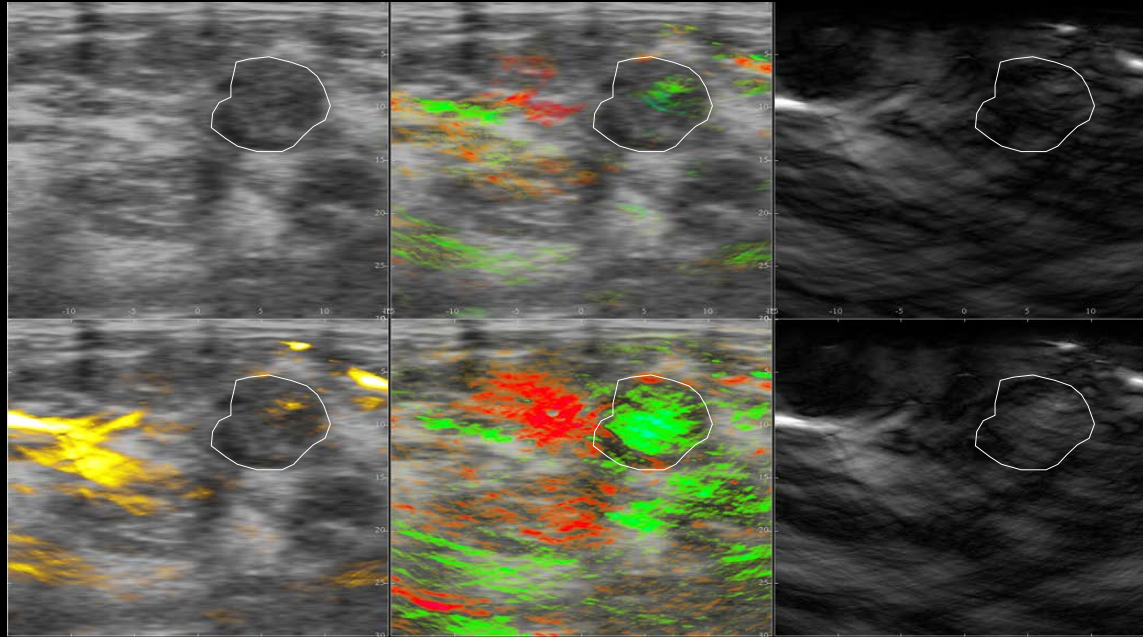
Fibroadenoma – Imagio – BI-RADS 4a



seno
MEDICAL INSTRUMENTS INC.™

Figure 2 displays a Fibroadenoma with normal polar branching feeding and draining vessels, capsular vessels, and mostly green internal blush.

Fibroadenoma – Imagio – BI-RADS 4a



seno
MEDICAL INSTRUMENTS INC.™

Figure 3 displays a true negative Fibroadenoma with left draining veins and capsular tributaries and a pure green internal signal exceeding that of the background tissue at the same depth.

Conclusion

- Preliminary data suggest that Imagio opto-acoustics has the ability to achieve stand-alone clinically meaningful sensitivity and specificity in a diagnostic setting.
- The internal opto-acoustic features are highly predictive consistent with the design of the co-registered methodologies. These features each carry prognosis.
- Prospective research to evaluate this technology is currently underway for regulatory review when it is complete.